

## SEVERE COMPLICATIONS FOLLOWING DIAGNOSTIC COLONOSCOPY: A REPORT OF TWO CASES

### Poważne komplikacje po kolonoskopii diagnostycznej – opis dwóch przypadków



Piotr Misiak, Sławomir Jabłoński, Szymon Wciśło, Maciej Niemirowicz

Uniwersytecki Szpital Kliniczny nr 2 im. Wojskowej Akademii Medycznej w Łodzi

Pielęgniarstwo Chirurgiczne i Angiologiczne 2014; 2: 82–84

Submitted: 22.01.2014; accepted: 1.05.2014

Address for correspondence:

Piotr Misiak, Uniwersytecki Szpital Kliniczny nr 2 im. Wojskowej Akademii Medycznej w Łodzi, e-mail: pitmis@interia.pl

#### Summary

Colonic perforation after diagnostic colonoscopy is an unusual complication. We would like to present two clinical cases of these unfavorable outcomes: first with bilateral pneumothorax, pneumoperitoneum and pneumoretroperitoneum and second with a cardiac arrest due to tension pneumothorax with pneumomediastinum and pneumoperitoneum. To our knowledge, there are less than five such cases described so far.

**Key words:** pneumothorax, diagnostic colonoscopy.

#### Streszczenie

Perforacja okrężnicy po kolonoskopii diagnostycznej jest niezwykle rzadkim powikłaniem. W poniższej pracy chcielibyśmy zaprezentować dwa przypadki, w których perforacja podczas kolonoskopii doprowadziła do sytuacji zagrożenia życia: pierwszy z dwustronną odmą opłuczną, odmą jamy otrzewnej i przestrzeni zaotrzewnowej oraz drugi, w którym na skutek masywnej odmy prężnej doszło do zatrzymania akcji serca.

Według naszej wiedzy w piśmiennictwie międzynarodowym dotychczas opisano ok. 5 podobnych przypadków.

**Słowa kluczowe:** odma prężna, kolonoskopia diagnostyczna.

#### Introduction

The number of patients undergoing endoscopic examination of the large intestine for various purposes such as screening and surveillance of colorectal cancer is still increasing. The majority of these examinations are performed in outpatient clinics without hospitalizations but only with a short period of observation afterwards. Colonic perforation during colonoscopy occurs rarely, but this is a complication with a high rate of morbidity and mortality. The frequency of perforations could be as low as 0.02% in diagnostic colonoscopy and as high as 2% for therapeutic colonoscopy [1, 2]. We would like to present two different cases of colonic perforations which were treated in our clinic.

#### Case reports

A 78-year-old female underwent colonoscopy in our hospital for investigation of weight loss (16 kg in two months) and anemia. She had no past history of cardi-

ovascular and pulmonary disease. Previous upper gastrointestinal endoscopy showed no pathology. On the day of the planned endoscopy procedure her vital signs were within normal limits. Colonoscopy was performed in the left lateral position without any sedation (only intravenous administration of painkillers and premedication with a low dose of benzodiazepine). The colonoscope was introduced to the sigmoid colon. A few minutes after starting the procedure the patient started to complain of severe abdominal and chest pain. Meanwhile at a height of 20 centimeters from the entrance to the anal canal, the endoscopist discovered laceration of the serosal layer at the border of sigmoid diverticulum, thus the examination was stopped immediately. The patient was stable and awake. The fast CT examination of the abdomen and chest cavity was performed. This demonstrated bilateral pneumothorax occupying approximately 20% of capacity of each: pleural cavities, pneumoperitoneum and pneumoretroperitoneum extending down to the perirectal region with extensive intramuscular and subcutaneous emphysema (Fig. 1

and 2). The patient was qualified to the bilateral pleural cavity drainage and urgent laparotomy afterwards. During the laparotomy we had problems with localization of the place of perforation so we asked for intraoperative endoscopy. We found an approximately 1 mm perforation in the distal part of the sigmoid colon, we decided to perform the primary suture and after the leak test we closed the abdomen. The postoperative period was uneventful and the patient was discharged on the 5<sup>th</sup> day.

A 71-year-old female underwent colonoscopy in a private endoscopy clinic. According to the documentation, she was qualified to endoscopy examination due to gastrointestinal bleeding. The patient was examined under intravenous sedation (TIVA), her vital signs were monitored continuously using a cardiomonitor. According to the documentation, the first 10 minutes of examination were uneventful, at the end of the examination of her transverse colon, the patient developed ventricular tachycardia. The endoscopist conducting the examination noticed enormous abdominal distension. The patient started to manifest difficulty in breathing. Finally, her state rapidly deteriorated and progressed to a cardiac arrest. The procedure was stopped and the cardiopulmonary resuscitation was begun according to ALS standards. After successful reanimation she was transported by an ambulance initially to the ICU unit of our hospital. On admission we performed CT examination of the thorax and abdominal cavity. The CT scans revealed left pneumothorax with a shift of the central mediastinum to the opposite side and pneumoperitoneum. Thus, the patient was qualified to drainage of the left pleural cavity and laparotomy. Intraoperatively we found a perforation of 0.5 cm length in the sigmoid. The perforation was probably caused by an iatrogenic injury. We performed primary sutures of the perforation (double layered), we also put the drain near the injured place. The patient was under our observation for 5 consecutive days, her further hospitalization was uneventful.

## Discussion

The incidence of a colonic perforation can range between 0.2% and 2%. The reported morbidity following

colonic perforation can be as low as 0.058% and as high as 40%, mortality ranges from 0% to 14% depending on patients' coexisting risk factors such as: age, medical history (co-morbidities and previous therapeutical procedures) [1-3]. Endoscopy-related complications could result from preparation for the procedure (mechanical bowel preparation), or they could be related directly to the endoscopic procedure. The three reasons which may potentially cause colonic perforation are barotrauma, mechanical trauma and trauma related directly to the therapeutic procedure. We report two cases of perforation of the large intestine during diagnostic colonoscopy, in which insufflated air leads to developing a whole spectrum of severe complications: pneumothorax, pneumoperitoneum and retroperitoneum. Intraoperatively we confirmed the place of perforation in one case and we needed assistance of the endoscopist, but interestingly, pneumoperitoneum can present without any perforation in approximately 15% of cases [4]. The potential reason for pneumoperitoneum without perforation may be previous intestinal operation with anastomoses which are a place of reduced resistance and also during the forcible air insufflation, the internal hernia of the colonic mucosa may occur, usually at the diverticulum site [3]. These places are more permeable to air. Air may pass into the abdomen or thorax by a number of different routes. The air may directly go to the retroperitoneal space and, than thanks to the anatomical connection to the mediastinal space. Maunder *et al.* was the first to describe this connection [4]. The visceral space starts from the cervical area and downwards with esophagus to mediastinum and further through the diaphragmatic hiatus into the abdomen, to the retroperitoneal space. Rupture of the mediastinal pleura in the case of pneumomediastinum can lead to pneumothorax or even tension pneumothorax. Alternatively, air from the peritoneal cavity can go directly through small diaphragmatic fenestrations to the pleural cavity, what may also end up as pneumothorax.

The way of management is still disputable especially in the case of pneumoperitoneum without perforation what may occur in 5-15% of cases [5, 6]. Some authors believe that when there is no leakage of con-

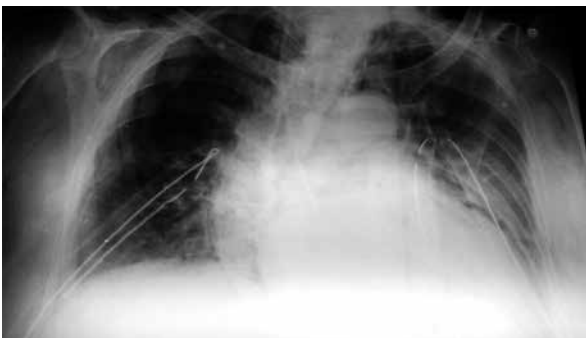


Fig. 1. Bilateral drainage of pleural cavity

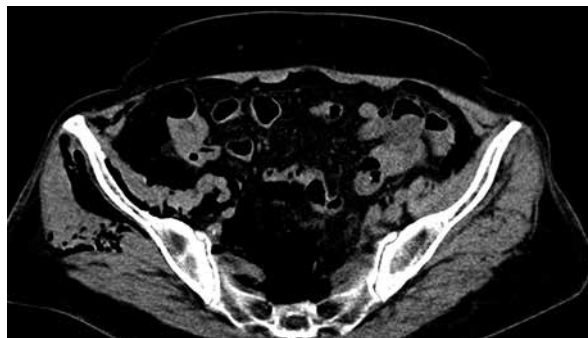

Fig. 2. Retroperitoneum

trast from the large intestine to the peritoneal cavity (CT with a water-soluble contrast agent) or any other pathological findings except air, the conservative way of treatment may be applied [3, 5, 6]. However, given the high risk of misdiagnosis of additional examinations and high risk of mortality in the case of diffuse peritonitis (up to 14%), many authors (including us) insist on quick surgical management [1, 2].

Most of patients are well prepared to colonoscopy by use of laxatives the day before, thus in most cases there is no contamination of the peritoneal cavity intraoperatively and initial repair of perforation, like in our cases, is possible (in other centers, the percentage of primary suture can be 30-60%). In the case of contamination we, just as other authors, prefer decompressive colostomy but the final way of treatment is always established intraoperatively [1, 7-9].

## Conclusions

The number of patients undergoing endoscopic examinations of the large intestine is still increasing. A lot of these examinations are carried out in outpatient private clinics. The onset of clinical symptoms of perforation during endoscopy may be latent or from the beginning very severe and they may lead to life-threatening situations. Therefore, we have to take into consideration the possibility of such complications, especially in elderly patients with multiple comorbidities and after the earlier surgical procedure within the large intestine.

## References

1. Lohsiriwat V, Sujarittanakarn S, Akaraviputh T, et al. Colonoscopic perforation: A report from World Gastroenterology Organization endoscopy training center in Thailand. *World J Gastroenterol* 2008; 14: 6722-6725.
2. Souadka A, Mohsine R, Ifrine L, et al. Acute abdominal syndrome complicating a colonoscopic perforation: a case report. *J Med Case Rep* 2012; 6: 51.
3. Marwan K, Farmer KC, Varley C, Chapple KS. Pneumothorax, pneumomediastinum, pneumoperitoneum, pneumoretroperitoneum and subcutaneous emphysema following diagnostic colonoscopy. *Ann R Coll Surg Engl* 2007; 89: W20-1.
4. Maunder RJ, Pierson DJ, Hudson LD. Subcutaneous and mediastinal emphysema. Pathophysiology, diagnosis, and management. *Arch Intern Med* 1984; 144: 1447-53.
5. Piotrowicz G, Opala M, Sapieżko J. Benign pneumoperitoneum – complications after colonoscopy. *Prz Gastroenterol* 2012; 7: 49-51.
6. Pouramand A, Shokoohi H. Tension pneumothorax, pneumoperitoneum and cervical emphysema following a diagnostic colonoscopy. *Case Rep Emerg Med* 2013; 2013: 583287.
7. Garbay JR, Suc B, Rotman N, et al. Multicentre study of surgical complications of colonoscopy. *Br J Surg* 1996; 83: 42-44.
8. Lüning TH, Keemers-Gels ME, Barendregt WB, et al. Colonoscopic perforations: a review of 30,366 patients. *Surg Endosc* 2007; 21: 994-997.
9. Iqbal CW, Chun YS, Farley DR. Colonoscopic perforations: a retrospective review. *J Gastrointest Surg* 2005; 9: 1229-1235.